

CASE STUDY

- 53% WOUND REDUCTION IN 8 WEEKS
- 7 ACTIGRAFT APPLICATIONS

PATIENT:

82 Year Old, Male

PAST MEDICAL HISTORY:

HTN, venous insufficiency, COPD

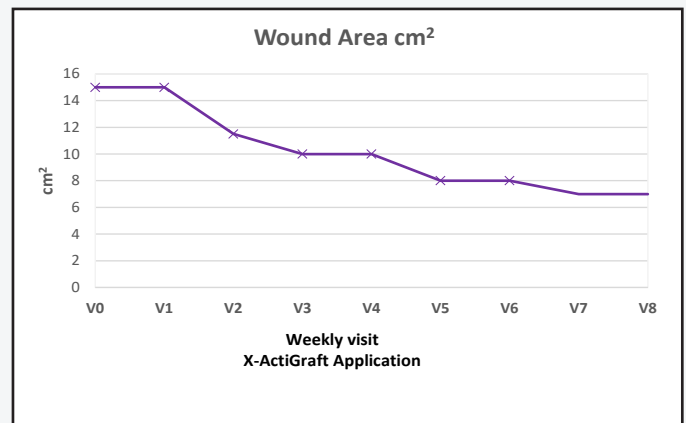
WOUND HISTORY:

- 8-month-old sacral skin flap dehiscence wound

PAST TREATMENTS:

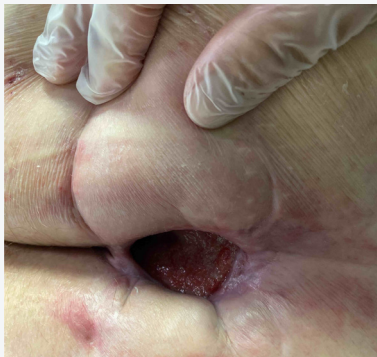Two skin flaps failures, several surgical debridements, negative pressure wound therapy (NPWT) for 5 months, one placement of skin graft substitute EpiFix®, two months of bi-weekly Endoform® (ovine matrix) placement

ACTIGRAFT TREATMENT PROGRESSION:



V=Weekly Application

Week 1



Week 8

